

## ABOUT THE AUTHORS



### **Ravi Dookeran, MD**

Dr. Dookeran has been working in Winnipeg since 2006 in the Misericordia Hospital and Winnipeg Clinic. He runs a surgical and medical Retinal practice serving all of Manitoba, Nunavut and western Ontario. After completing his medical school training at the University of Manitoba and ophthalmology residency in Edmonton at the University of Alberta, Dr. Dookeran went on to complete a 2-year surgical and medical Retina fellowship at McGill University. Dr. Dookeran is an Assistant Professor in the Department of Ophthalmology at the University of Manitoba and is actively involved in clinical research having authored numerous publications. He has served as Faculty Lead for the retina section of the ophthalmology residency program and on the Residency Program Committee for over 8 years. He received the “Teacher of the Year” award in 2017 for his excellence and commitment to teaching. As an active speaker, Dr. Dookeran has given lectures and spoken at conferences at a local, national and international level and even worked with The Learning Channel, participating in the medical educational series Doctorology with Canadian comedian Leslie Nielsen. Dr. Dookeran has served on the national board of the CNIB Patient Advocacy Committee for 3 years and continues to work with government to help create policies that benefit the lives of the visually impaired across Canada. Dr. Dookeran has been actively involved in developing a Teleophthalmology program and serves as the medical director of the Manitoba Retinal Screening and Vision Program (MRSVP). This service has been successfully running since 2004, covering much of Northern Manitoba and has become one of the largest across Canada.

**Author Affiliations:** Assistant Professor, Department of Ophthalmology, University of Manitoba, Winnipeg, MB

## ABOUT THE AUTHORS



### Charbel Wahab, MD

Dr. Charbel Wahab is a surgical retina fellow at University of Manitoba – Misericordia Health Centre. He completed his medical degree as well as his Ophthalmology Residency at the University of Balamand in Lebanon. He has a Bachelor of Science in Biology from the University of Balamand. Dr. Wahab pursued his education and training by completing a Medical Retina Fellowship at the American University of Beirut in 2021-2022, followed by another Medical Retina and Uveitis Fellowship at the University of Toronto in 2022-2023. He has a clinical focus and interest in vitreoretinal diseases and retinal surgery. In addition, Dr. Wahab has a very keen interest in research and innovations in ophthalmology and has published several articles and presented at various meetings as well as participated in various extracurricular activities, committees, and volunteering.

**Author Affiliations:** University of Manitoba, Winnipeg, MB

# Peripheral Retinal Diseases: Indications for Prophylactic Laser Treatment versus Observation

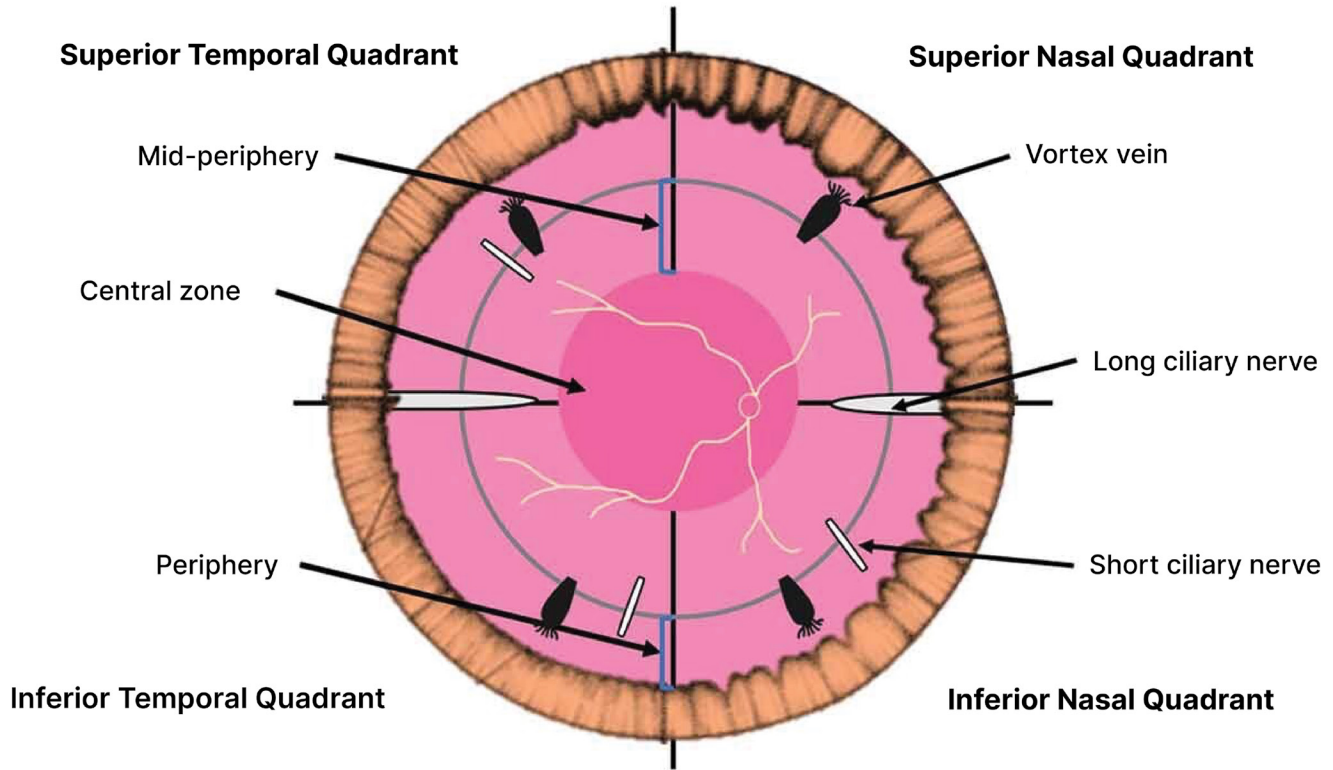
Ravi Dookeran, MD  
Charbel Wahab, MD

*Peripheral retinal diseases encompass a spectrum of conditions that can affect multiple layers of the retina, posing potential risks to visual function if left untreated. This article provides an overview of common peripheral retinal diseases, discusses the indications for prophylactic laser treatment versus observation, and highlights the factors that influence clinical decision-making in managing these conditions. Understanding the appropriate timing for intervention is crucial in preventing vision-threatening complications and optimizing visual outcomes.*

## Introduction

Peripheral retinal diseases encompass a diverse group of conditions that can impact visual health and function. While some of these conditions are asymptomatic and may have a benign course, others can progress to potentially

sight-threatening complications, such as retinal detachment, especially in the context of visual symptoms.<sup>1</sup> Careful clinical evaluation and timely intervention are essential in managing peripheral retinal diseases to prevent loss of visual acuity, particularly when predisposing risk factors are present. Obtaining a proper history may help



**Figure 1.** Four zones of the peripheral retina; courtesy of Cheung R, Ly A, Katalinic P et al. Visualization of peripheral retinal degenerations and anomalies with ocular imaging. *Seminars in Ophthalmology*. 2022 Mar 7;37(5):554-82.

identify some genetic conditions associated with higher incidence of retinal tears and detachment such as high myopia or Stickler syndrome. Other factors to consider include the new onset of symptoms of posterior vitreous detachment, prior history of trauma or relatively recent intraocular surgery such as cataract surgery, intravitreal injection or YAG capsulotomy.<sup>2</sup>

Retinal regions based on gross anatomy including vessels was defined in 1961 by Duke-Elder who categorized the peripheral retina into four zones: **1)** the near periphery, a 1.5 mm ring adjacent to the 6 mm diameter macula; **2)** the middle periphery, the next 1.5 mm ring; **3)** the far-periphery, measuring the next 9-10 mm on the temporal and 16 mm on the nasal side; **4)** the ora serrata or extreme periphery, measuring the additional 2.1 mm in the temporal and 0.7 mm on the nasal side (**Figure 1**).<sup>3,4</sup>

Peripheral degenerations can be divided into intraretinal, vitreoretinal and chorioretinal categories (**Table 1**).<sup>3</sup>

## Peripheral Degeneration

### A) Intraretinal

#### *Degenerative Retinoschisis*

Degenerative retinoschisis, also known as acquired or senile, is a rare eye disease characterized by the abnormal separation of the neurosensory retina layers due to microcystic degeneration, typically at the outer plexiform layer or inner nuclear layer (inner retinoschisis). Inner retinoschisis is more often seen in congenital retinoschisis (also called juvenile or X-linked retinoschisis).<sup>5</sup>

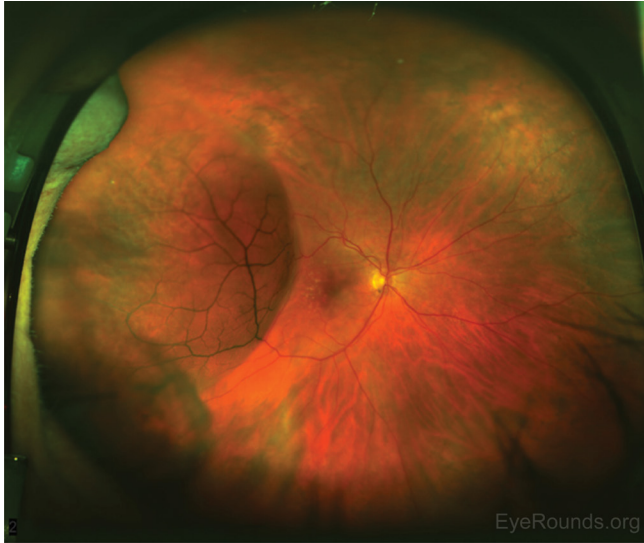Retinoschisis is commonly associated with myopia with a prevalence that varies being cited as being found in 2–7% of the general population in one study<sup>5</sup> to 22% in another.<sup>6</sup> It is more common in patients 40 years and older and has no sex predilection.<sup>5</sup> This lesion is a bullous elevation of the peripheral retina, found predominantly in the inferotemporal quadrant 72% and superotemporal 28%.<sup>6</sup> (**Figure 2a**). It is typically asymptomatic. The progression of a

Care Management	Management Options
Type of Lesion	Treatment*
Acute symptomatic horseshoe tears	Treat promptly
Acute symptomatic operculated holes	Treatment may not be necessary
Acute symptomatic dialyses	Treat promptly
Traumatic retinal breaks	Usually treated
Asymptomatic horseshoe tears (without subclinical RD)	Consider treatment unless there are signs of chronicity
Asymptomatic operculated tears	Treatment is rarely recommended
Asymptomatic atrophic round holes	Treatment is rarely recommended
Asymptomatic lattice degeneration without holes	Not treated unless PVD causes a horseshoe tear
Asymptomatic lattice degeneration with holes	Usually does not require treatment
Asymptomatic dialyses	No consensus on treatment and insufficient evidence to guide management
Eyes with atrophic holes or lattice degeneration where the fellow eye has had a RD	No consensus on treatment and insufficient evidence to guide management

**Table 1.** Management options for peripheral retinal lesions; adapted from American Academy of Ophthalmology. AAO PPP Retina/Vitreous Committee, Hoskins Center for Quality Eye Care. Preferred Practice Pattern: Posterior Vitreous Detachment, Retinal Breaks, and Lattice Degeneration PPP 2022.

**Abbreviations:** PVD: posterior vitreous detachment, RD: retinal detachment

\*There is insufficient evidence to recommend prophylaxis of asymptomatic retinal breaks for patients undergoing cataract surgery.



**Figure 2a.** Fundus photo showing temporal retinoschisis (RS) from 7:00 to 10:00 without identified inner, outer, or full-thickness retinal breaks extending into the temporal macula<sup>7</sup>; photo courtesy of Ravi Dookeran, MD and Charbel Wahab, MD.

schisis cavity is rare and patients typically don't become symptomatic until it reaches the arcades. Retinoschisis may demonstrate outer retinal breaks that may lead to detachment of the neurosensory retina. These are known as a schisis-detachment and can remain static and contained. Should there be an inner retinal break then communication with the vitreous can result in a rhegmatogenous detachment requiring surgical repair. Given the rarity of this type of progression there are no adequate case series guiding management and observation is usually recommended. If documented progression of a schisis cavity through clinical exam, fundus photography and/or OCT is present then it may be treated with argon laser photocoagulation notably if patients are increasingly symptomatic (Figure 2b and 2c).<sup>6</sup>

### **White Without Pressure**

White without pressure presents as irregular, translucent areas in the retinal periphery, sometimes with a red-brown border (Figure 3).<sup>9</sup> Lesions are usually located beyond the equator, although changes may occur near the major retinal vascular arcades. WWOP is often bilateral, and is typically found in up to 30% of normal eyes and in young myopic patients. This degeneration can be mistaken for retinal detachment or retinoschisis. The exact etiology is still unknown; one

perspective suggests that it is a result of traction on the peripheral vitreous, while another viewpoint holds that it is merely an abnormal light reflex originating from a structurally normal interface within the vitreoretinal system due to increased density of collagen bundles at the vitreous base. Optical coherence tomography (OCT) shows white areas that correspond to hyperreflective outer retinal layers and ellipsoid zone, with no vitreous traction.

There is no need for prophylactic laser as it has low risk for association with retinal detachment. Patients can be monitored with dilated fundus examinations every 1–2 years.

### **White With Pressure**

White with pressure presents with a distinctive milky white or opalescent appearance of the peripheral retina observed in many normal eyes when examined with scleral depression. It is the term used to describe flat peripheral detachment without any retinal break (Figure 4).<sup>9</sup>

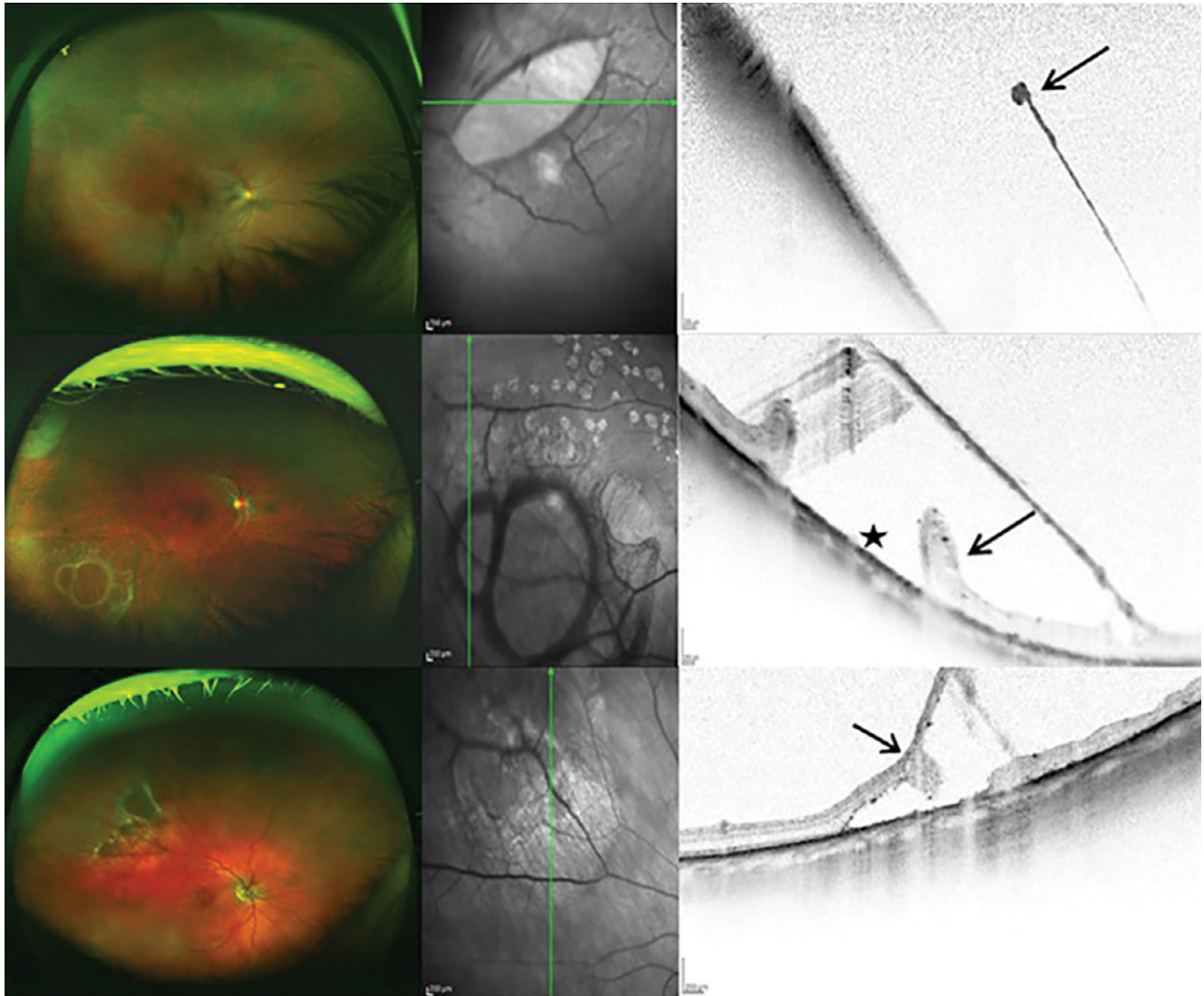
It must be carefully distinguished from a subclinical peripheral retinal detachment. The retina appears normal without scleral depression. It is a benign condition and is not associated with retinal breaks, thus no prophylactic treatment is needed.

### **Dark Without Pressure**

Dark without pressure (DWOP) is defined as a hypopigmented lesion region with the border of DWOP corresponding to the site where the ellipsoid zone has faded or disappeared (Figure 5).<sup>10</sup> It is typically asymptomatic and benign, without need for prophylactic laser.

### **Peripheral Cystoid Degeneration**

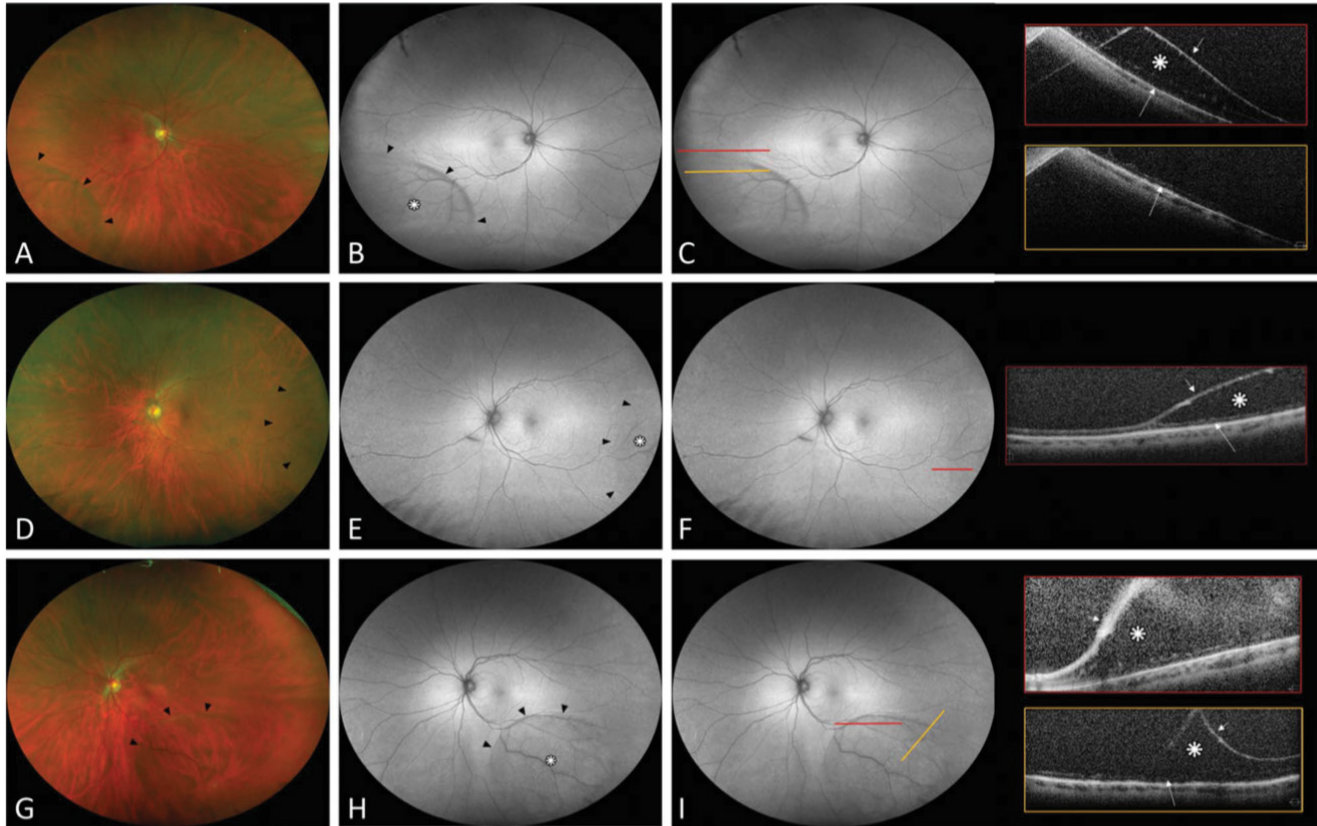
Peripheral cystoid degeneration, a common occurrence characterized by tiny cyst-like spaces observed in the layers from inner to outer plexiform layers, has been identified in approximately 87% of autopsy eyes across various age groups, and virtually 100% of eyes in older individuals as a result of aging (Figure 6).<sup>11</sup> Additionally, current research on preventing rhegmatogenous retinal detachment lacks substantial evidence to strongly advocate for preventive treatment of lesions beyond symptomatic flap tears.<sup>11</sup>



**Figure 2b. Top row:** The fundus photograph (left) of the right eye shows a superotemporal RS with inner-layer break (ILB). The horizontal green line of the infrared photograph (middle) indicates the exact location of the optical coherence tomography (OCT) scan of the ILB. The corresponding OCT scan (right) shows the interruption of the atrophic inner leaf (arrow).

**Middle row:** The fundus photograph (left) of the right eye shows an RS with multiple outer-layer (OL) breaks. The infrared photograph (middle) shows the exact location of the OCT scan of the OL breaks (vertical green line). The corresponding OCT scan (right) of the OL break shows the attached outer leaf with rolled-up edges (arrow) and the tissue retraction (star).

**Bottom row:** The fundus photograph (left) of the right eye pictures a superotemporal RS and an OL break. The vertical green line of the infrared photograph (middle) shows the exact location of the OCT scan (right), where a tissue retraction with a smooth edge and intraschisis pillar (arrow) is shown; *photo courtesy of Ravi Dookeran, MD and Charbel Wahab, MD.*



**Figure 2c.** Detection of Neurosensory Retinal Detachment Complicating Degenerative Retinoschisis by Ultra-Wide Field Fundus Autofluorescence Imaging. RETINA 2020; courtesy of Francone et al.

Ultra-widefield fundus autofluorescence and spectral domain OCT findings in degenerative RS without neurosensory retinal detachment. **Group B:** no hyperautofluorescence present. **A, D, and G:** Ultra-widefield color fundus photographs showing degenerative RS (black arrowheads). **B, E, and H:** Ultra-widefield fundus autofluorescence demonstrating the area of RS as isoautofluorescence (white asterisk) with a hypoautofluorescence line (black arrowhead) at the posterior edge. **C, F, and I:** Colored lines indicate the exact location through which the OCT scans were taken. Scans show splitting of neurosensory retina: the schisis cavity (white asterisk), the detached inner retinal layer (short white arrow), and a thin irregular band of moderately reflective tissue over the RPE hyperreflective band corresponding to the outer retinal layer (white large arrow).

### Snowflake Degeneration

Snowflake degeneration manifests clinically with the emergence of minute crystalline deposits in the retina spanning from the ora serrata to the equator. Initially thought to be a form of retinitis pigmentosa, both clinical observations and genetic investigations affirm snowflake degeneration as a distinct disease entity (**Figure 7**).<sup>8</sup>

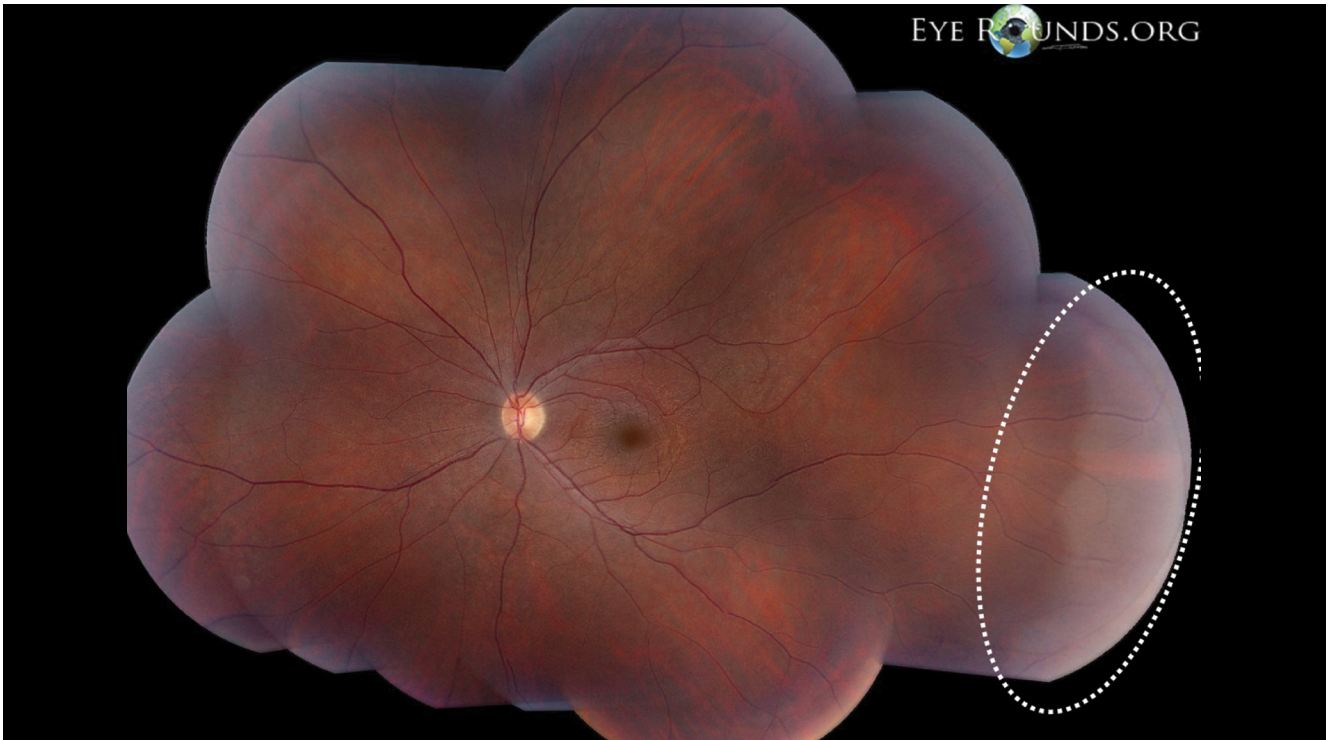
Some research studies recommend prophylactic laser while others do not.<sup>8</sup> It is generally recommended to observe unless other high-risk characteristics for retinal detachment coexist.

### B) Vitreoretinal

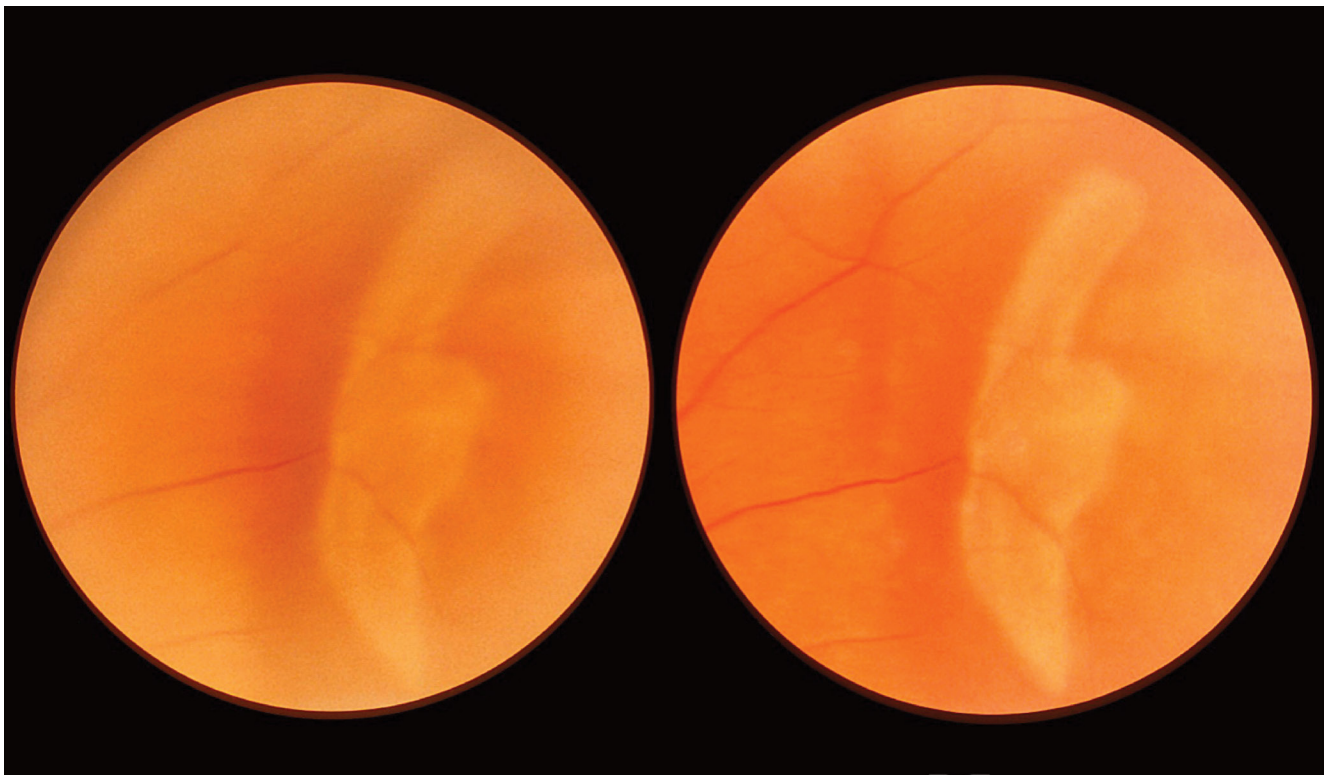
#### Lattice Degeneration

Lattice degeneration is a common peripheral retinal finding characterized by areas of retinal thinning and lattice-like appearances.

Lattice degeneration manifests as thinning of the retina accompanied by the absence of the neurosensory layer, along with prominent vitreoretinal adhesion surrounding the affected area. It is prevalent in approximately 6–8% of the general population's eyes<sup>12</sup> and can have a variety of presentations. It can be oriented circumferentially midway between the ora serrata and equator or may present radially along vessels

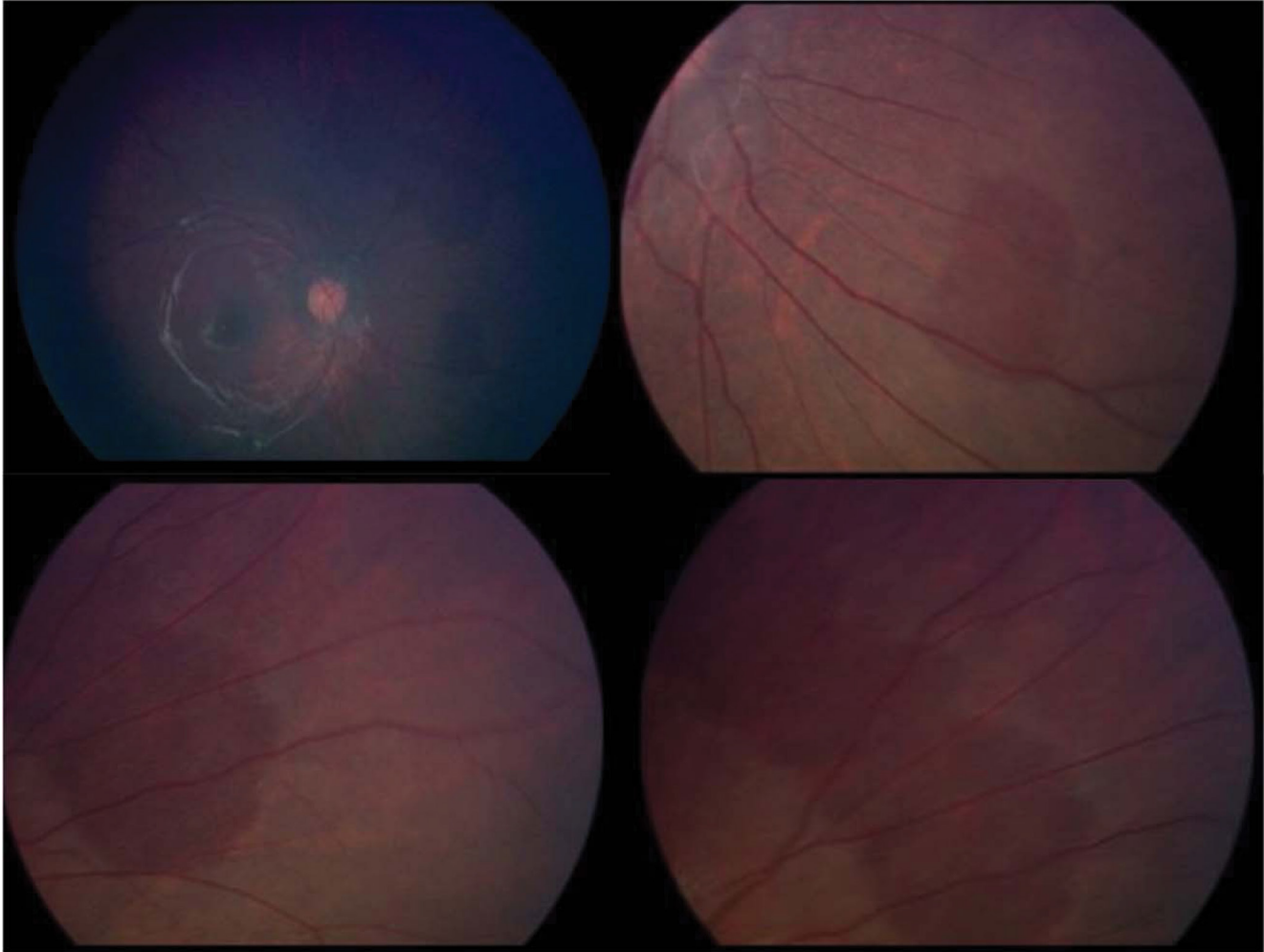


**Figure 3.** Wide field photo of the left eye showing white without pressure extending from 2 till 4 o'clock; *photo courtesy of Ravi Dookeran, MD and Charbel Wahab, MD.*



**Figure 4.** White with pressure observed during scleral depression; *photo courtesy of Ravi Dookeran, MD and Charbel Wahab, MD.*





**Figure 5.** Color fundus images of the right eye showing multiple flat patches of reddish dark retina with well-defined scalloped edges nasal to the optic nerve head; *courtesy of Flores Pimentel, M.A., Duncan, J.L., de Alba Campomanes, A.G. et al. Dark without pressure retinal changes in a paediatric age group. Eye. 35, 1221–1227 (2021).*

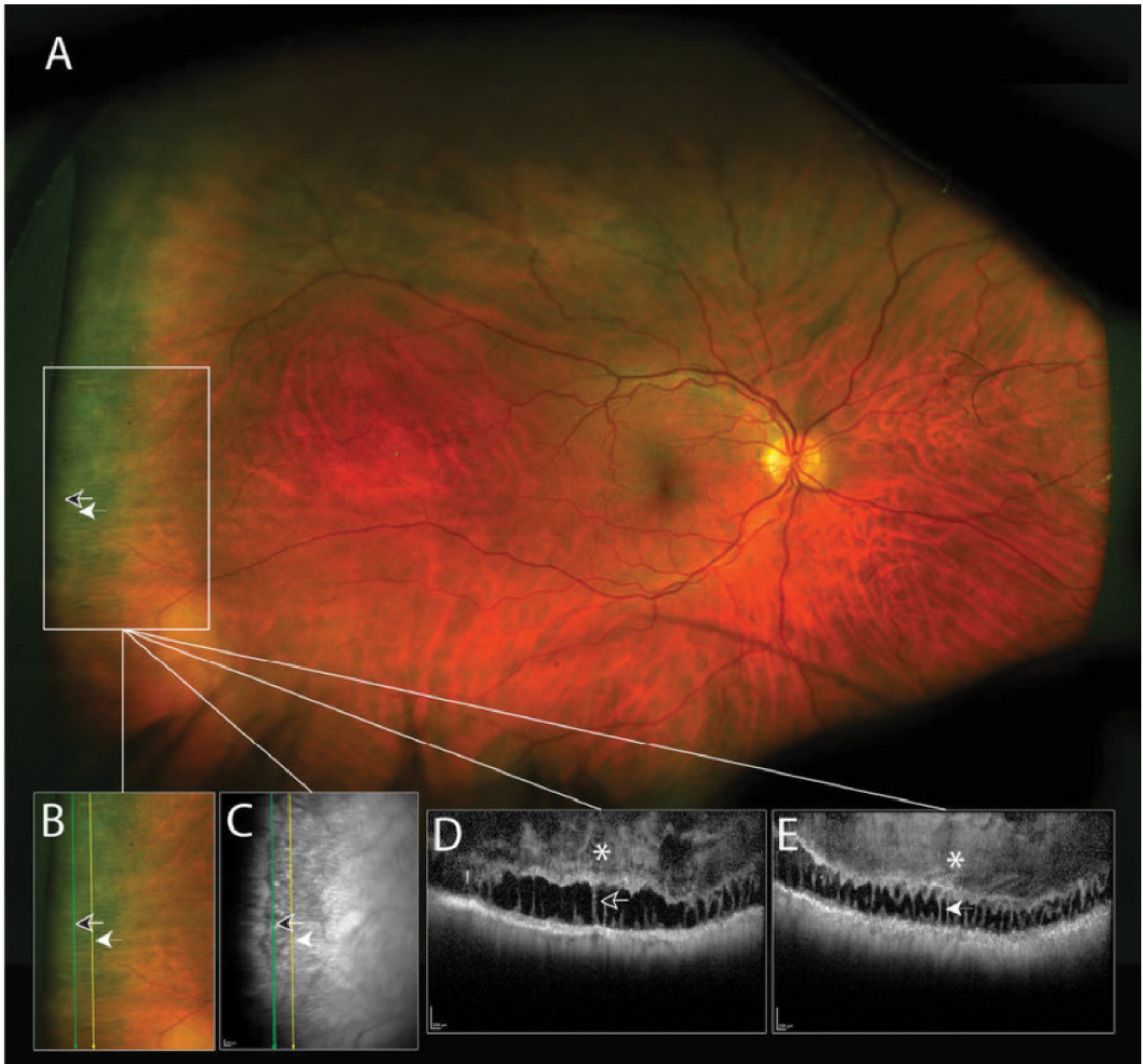
(radial perivascular lattice). This condition impacts both the retina and vitreous, representing a significant peripheral vitreoretinal degeneration that heightens the risk of retinal tears and rhegmatogenous retinal detachment due to traction from the vitreous (**Figure 8**).<sup>12</sup>

While most cases of lattice degeneration are benign and do not require intervention, patients with associated retinal holes or tears are at increased risk of retinal detachment. Twenty to 30% of all detachments occur in eyes that have lattice degeneration but are not necessarily causative. The presence of lattice increases the relative risk of detachment from 0.01% to 0.3%–0.5%<sup>13</sup>. Prophylactic laser treatment may be indicated in individuals with high-risk features such as flap tears, pseudophakia or aphakia,

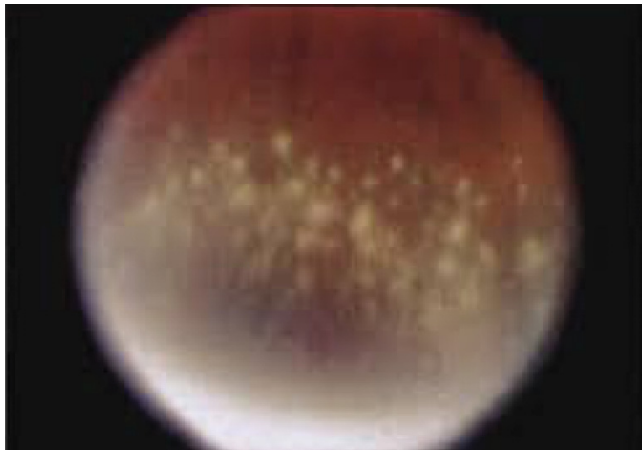
previous retinal detachment in the fellow eye, or a strong family history of retinal detachments. The acute onset of new symptoms (floaters and/or photopsia) is a significant risk factor for developing a retinal detachment warranting laser retinopexy. Close observation is recommended for asymptomatic individuals with isolated lattice degeneration and no high-risk factors. High myopia (>6 diopters) with greater than 6 clock hours of lattice should also be observed.

#### ***Lattice as a Risk Factor for Retinal Detachment or Tear Following Cataract Surgery***

With the evolution of microincisional cataract surgery the incidence of rhegmatogenous retinal detachment (RRD) and retinal tear (RT) have decreased. Prior to small incision



**Figure 6.** Wide field photo of the right eye with spectral domain OCT over the peripheral cystoid degeneration demonstrating saw-tooth patterns which are comprised of hyporeflective cystoid cavities and broad columns; courtesy of Choudhry N, Golding J, Manry MW, Rao RC. *Ultra-Widefield Steering-Based Spectral-Domain Optical Coherence Tomography Imaging of the Retinal Periphery. Ophthalmology.* 2016 Jun;123(6):1368–74.



**Figure 7.** Snowflake degeneration; courtesy of Robertson DM, Link TP, Rostvold JA. Snowflake Degeneration of the Retina. *Ophthalmology*. 1982 Dec;89(12):1513–7.

surgery previous studies cited incidence of RRD at 0.6%–1.7%, whereas a study of greater than 3 million cataract surgeries performed in the US between 2014–2017 found the incidence reduced to 0.21% (roughly 1 in 500) in the first year.<sup>14</sup>

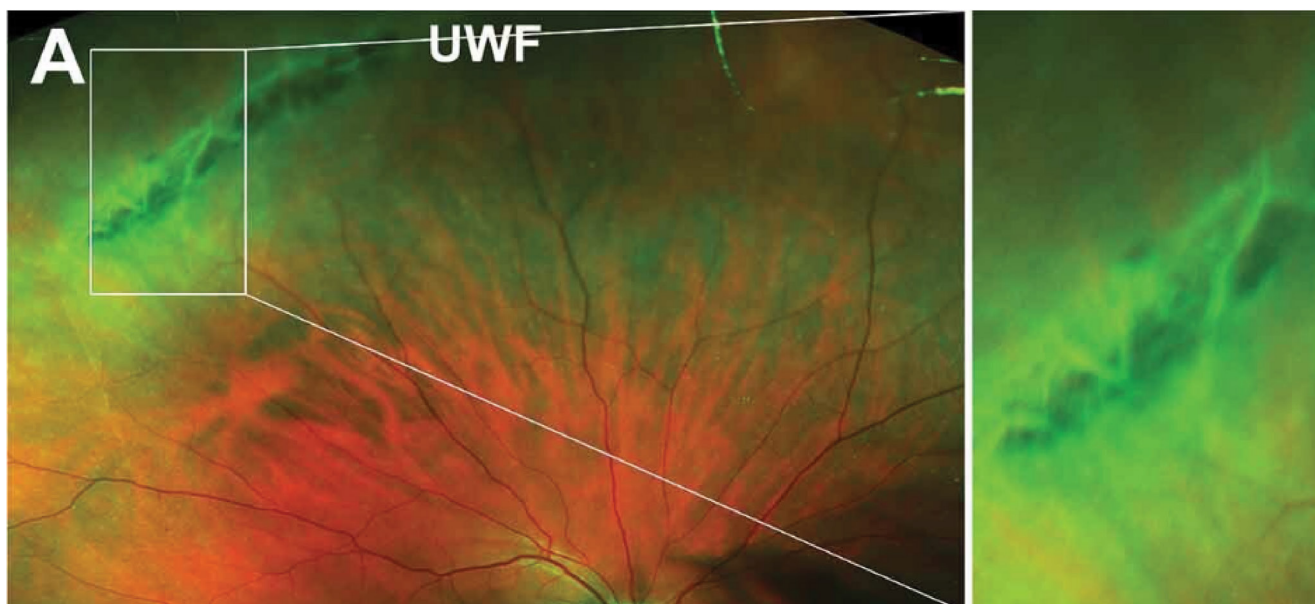This study found the incidence of retinal tear to be 0.17% and found certain risk factors associated with RRD and RT. These include male, younger age (<70), lattice degeneration, high myopia, posterior vitreous detachment, mature

cataract and complicated surgery (as identified by code). The greatest increased risk was with lattice degeneration at 1.44%. The odds ratio for RRD and RT with lattice was 10.53 and 43.86 respectively.<sup>14</sup> It is unclear whether this apparent increased risk confers some bias in detection post cataract surgery due to clearing of the opacity, but it acknowledges that further studies are needed to determine whether this risk can be reduced with early treatment to the lattice. The overall magnitude of the increased risk of RRD and RT, however, warrants careful evaluation to identify lattice degeneration and consideration of treatment versus close monitoring when counselling individual patients on the risks associated with cataract surgery.

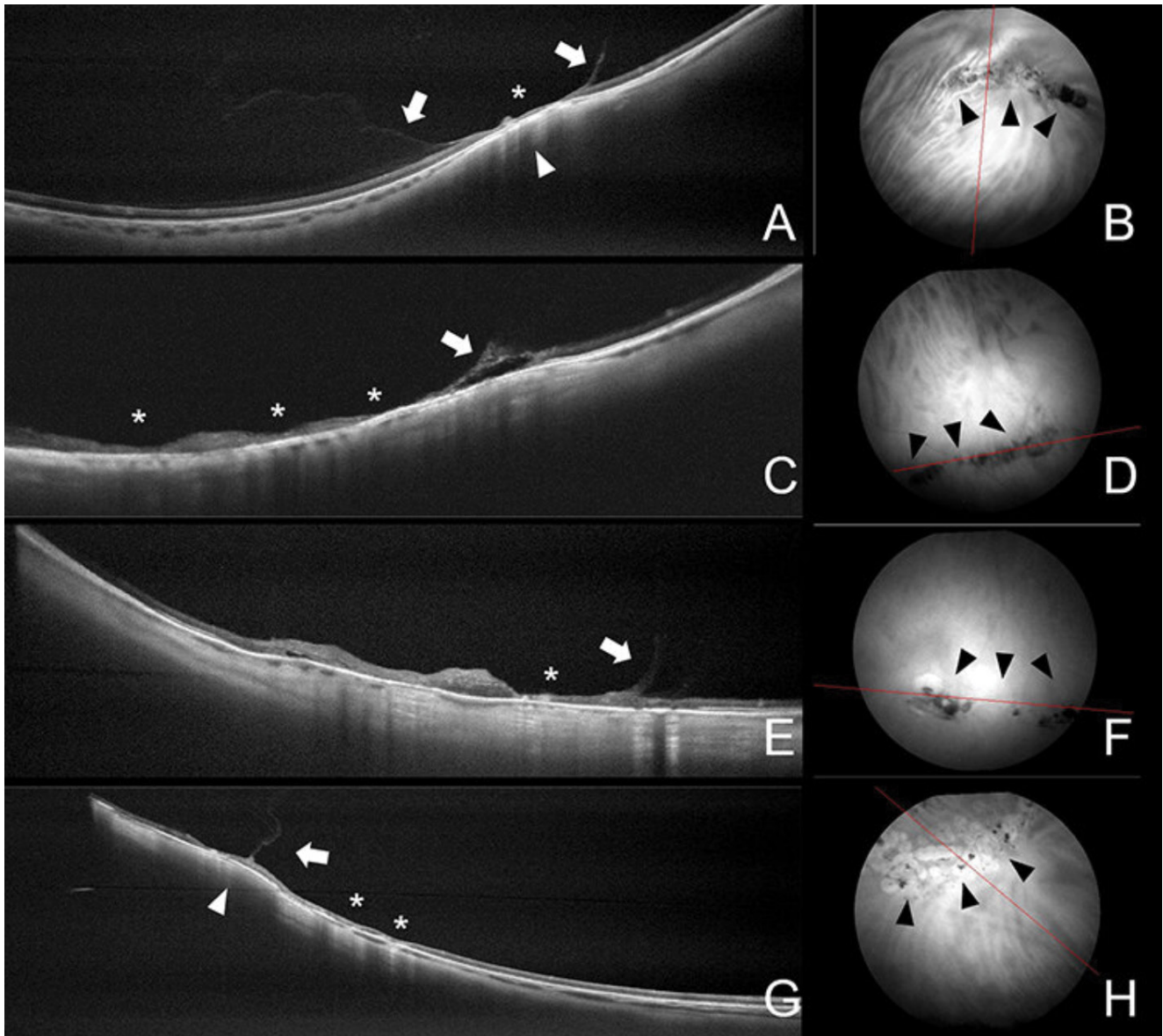
### Snail Track Degeneration

Snail track degeneration manifests as closely positioned shiny, crinkled or frosted bands within the retina, resembling the tracks left by a snail. These formations, comprised of pinpoint glistening white dots, are also clearly observable through red-free ultra-widefield imaging. On OCT, the lesions present as irregular thinning and a wrinkled curvilinear inner retinal surface, potentially lacking traction, or condensation of the overlying vitreous (**Figure 9**).<sup>8</sup>

Snail track lesions have not been associated with an increased risk of retinal breaks or retinal

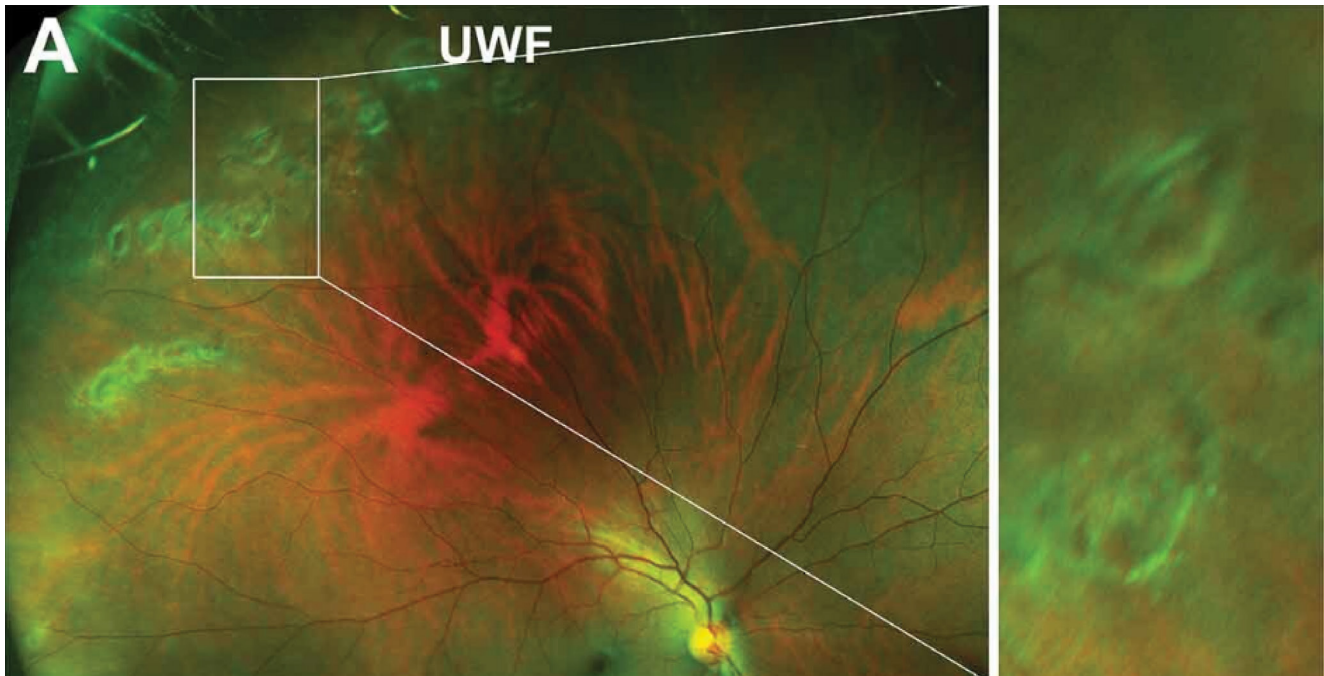


**Figure 8a.** Area of lattice degeneration at the periphery of the right eye in the supertemporal area; courtesy of Cheung R, Ly A, Katalinic P, Minas Theodore Coroneo, Chang A, Kalloniatis M, et al. Visualisation of peripheral retinal degenerations and anomalies with ocular imaging. *Seminars in Ophthalmology*. 2022 Mar 7;37(5):554–82.

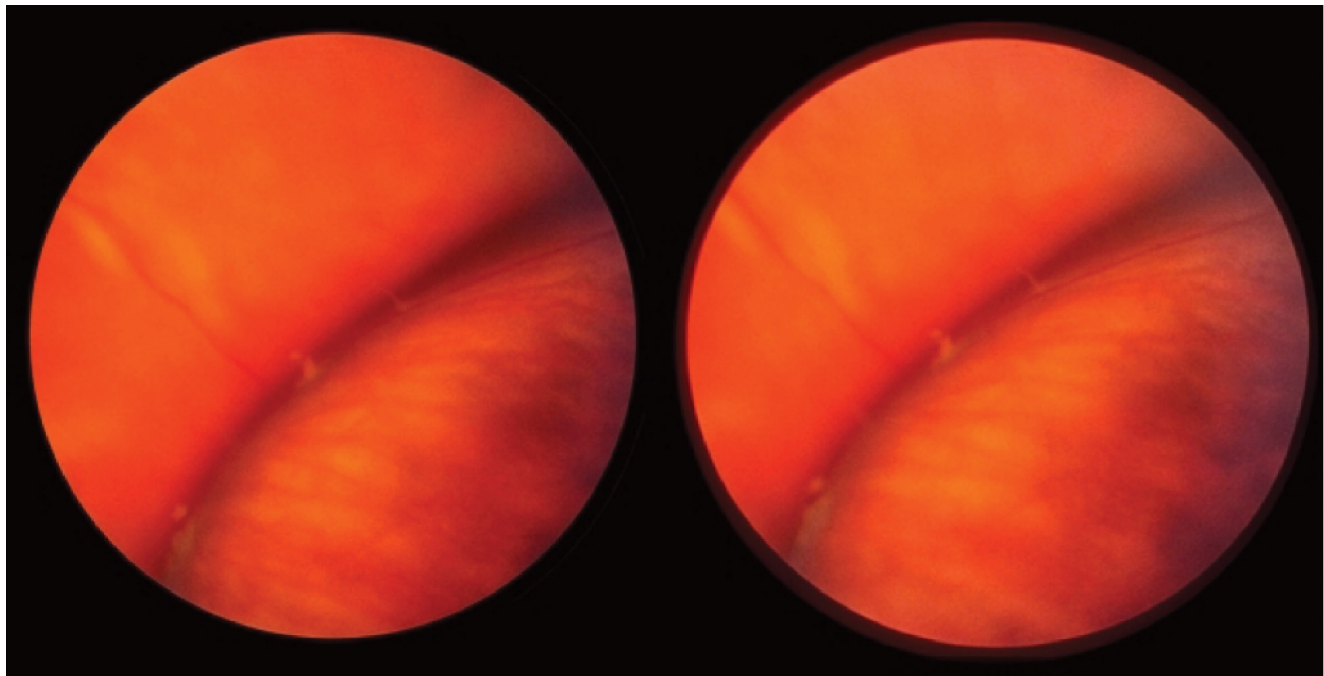


**Figure 8b.** Spotlight on Lattice Degeneration Imaging Techniques; *courtesy of Maltsev et al. Clinical Ophthalmology 2023;17 2383–2395.*

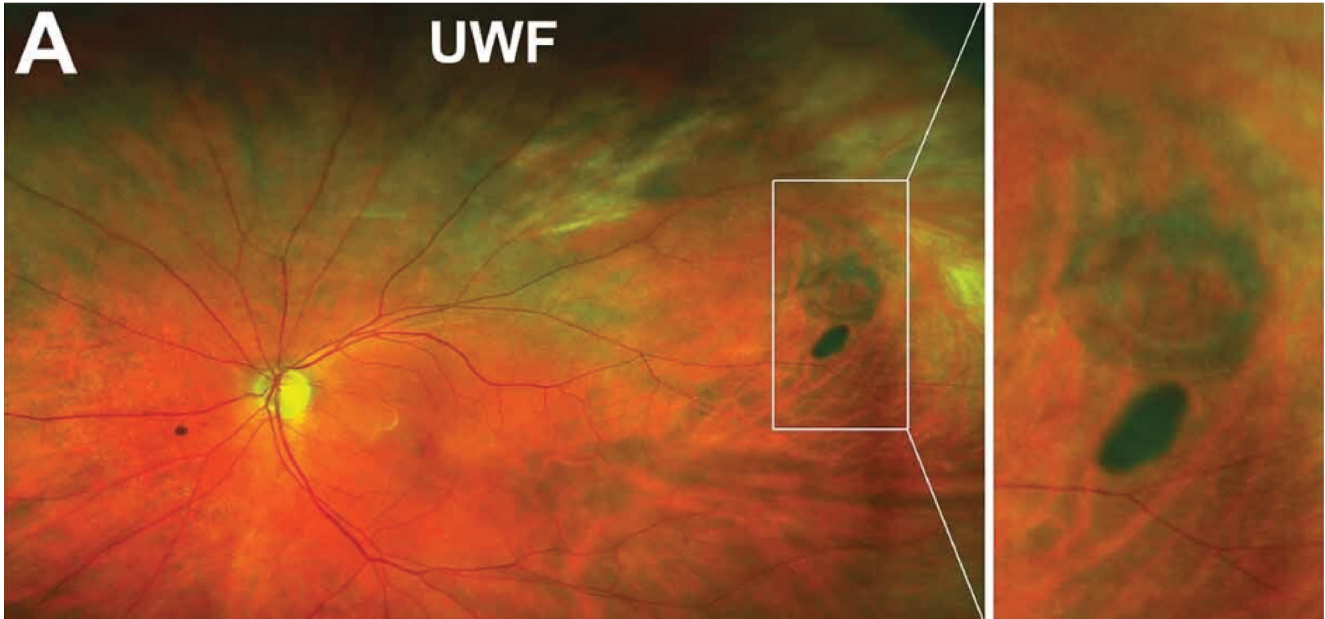
Optical coherence tomography findings in lattice degeneration. **(A)** Cross-sectional scan passing the lesion crosswise demonstrates U-shaped vitreous adhesion and liquification (arrows), retinal and choroidal thinning (asterisk), and dome-shaped scleral indentation (arrowhead). **(B)** Corresponding infrared image shows perivascular moderately pigmented lesion (black arrowheads) (position of the scan is indicated by the red line). **(C)** Cross-sectional scan passing along the lesion demonstrates retinal and choroidal thinning (asterisks) and retinal separation (arrow). **(D)** Corresponding infrared image shows concentric highly pigmented lesion (black arrowheads) (position of the scan is indicated by the red line). **(E)** Cross-sectional scan passing along the lesion demonstrates retinal and choroidal thinning (asterisks) and vitreous traction (arrow). **(F)** Corresponding infrared image shows concentric mildly pigmented lesion with chorioretinal atrophy (black arrowheads) (position of the scan is indicated by the red line). **(G)** Cross-sectional scan passing the lesion crosswise demonstrates chorioretinal scars after laser photocoagulation (asterisks), “blunted” vitreous traction (arrow), and dome-shaped scleral indentation (arrowhead). **(H)** Corresponding infrared image shows mildly pigmented lesion surrounded by chorioretinal scars after laser photocoagulation (black arrowheads) (position of the scan is indicated by the red line).



**Figure 9.** Snail track degeneration in the superotemporal peripheral retina of the right eye; *courtesy of Cheung R, Ly A, Katalinic P, Minas Theodore Coroneo, Chang A, Kalloniatis M, et al. Visualisation of peripheral retinal degenerations and anomalies with ocular imaging. Seminars in Ophthalmology. 2022 Mar 7;37(5):554–82.*



**Figure 10.** Retinal tufts identified by scleral depression; *photo courtesy of Ravi Dookeran, MD and Charbel Wahab, MD.*



**Figure 11.** Ultra-wide field photo of the left eye showing an operculated hole; courtesy of Cheung R, Ly A, Katalinic P, Minas Theodore Coroneo, Chang A, Kalloniatis M, et al. *Visualisation of peripheral retinal degenerations and anomalies with ocular imaging. Seminars in Ophthalmology. 2022 Mar 7;37(5):554–82.*

detachment, thus prophylactic laser retinopexy is not recommended.

### **Retinal Tufts**

Retinal tufts are regions of degeneration within the retina resulting from its adherence to and traction by the vitreous (Figure 10). They manifest in various forms such as cystic, non-cystic and zonular traction tufts. The prevalence varies, with non-cystic tufts found in as many as 72% of adults, cystic tufts in up to 5% and zonular traction tufts in up to 15%. These tufts may be associated with retinal breaks and tractional forces on the surrounding retina, predisposing patients to retinal detachment.<sup>8</sup> Prophylactic laser treatment is not recommended; routine monitoring is advised.

### **Retinal Holes and Tears**

Peripheral retinal holes and tears are focal defects in the retinal tissue that can predispose to retinal detachment, particularly if located in areas of lattice degeneration. Prophylactic laser photocoagulation is often recommended for symptomatic horseshoe tears and in select symptomatic operculated holes where signs of subretinal fluid or anterior traction are evident. Generally operculated holes warrant observation

only.<sup>2</sup> Close observation with serial examinations is justified for asymptomatic small holes or tears with surrounding pigmentation, with prompt treatment initiated if there are signs of progression or new symptoms (Figure 11).

### **Atrophic Holes**

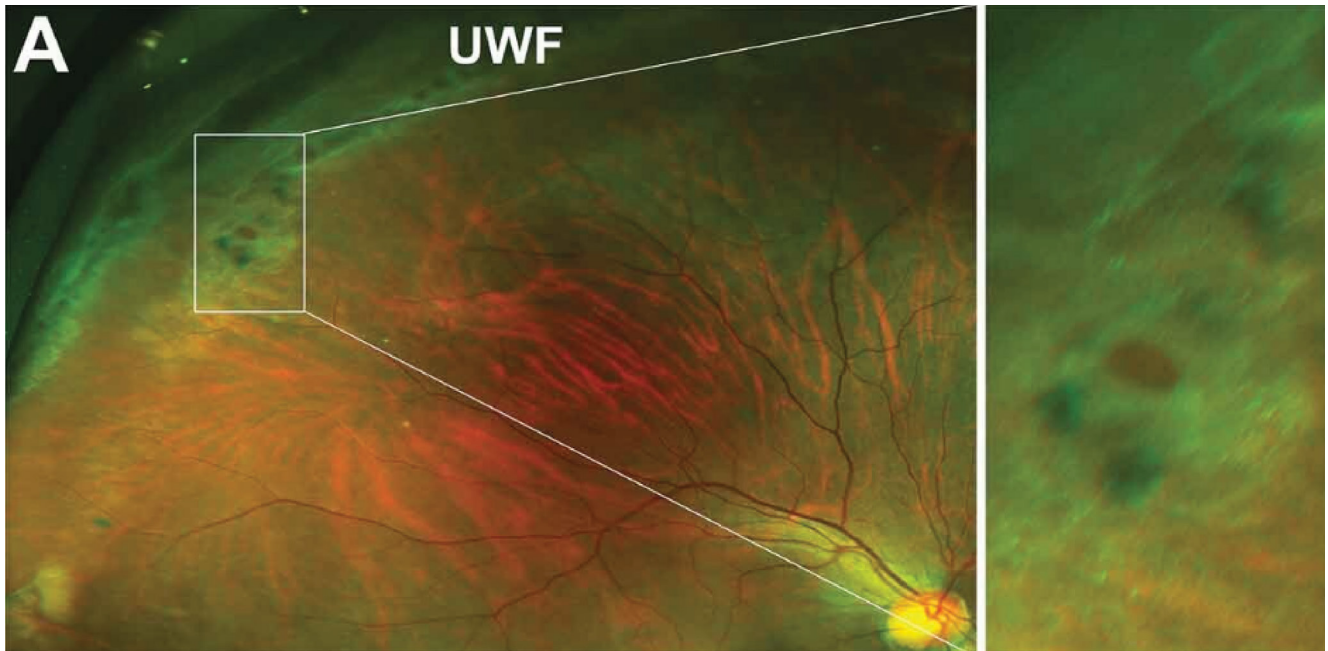
Atrophic holes are full-thickness defects in the neurosensory retina, typically found in the peripheral retina (Figure 12). These holes may result from a variety of etiologies, including lattice degeneration, trauma or myopia. Atrophic holes pose a risk for rhegmatogenous retinal detachment if they are located near areas of vitreoretinal adhesion. Clinical examination may reveal a circular or ovoid area of retinal thinning with surrounding pigment clumping.

There is consensus for observation over treatment of atrophic holes, especially asymptomatic atrophic holes.<sup>2</sup>

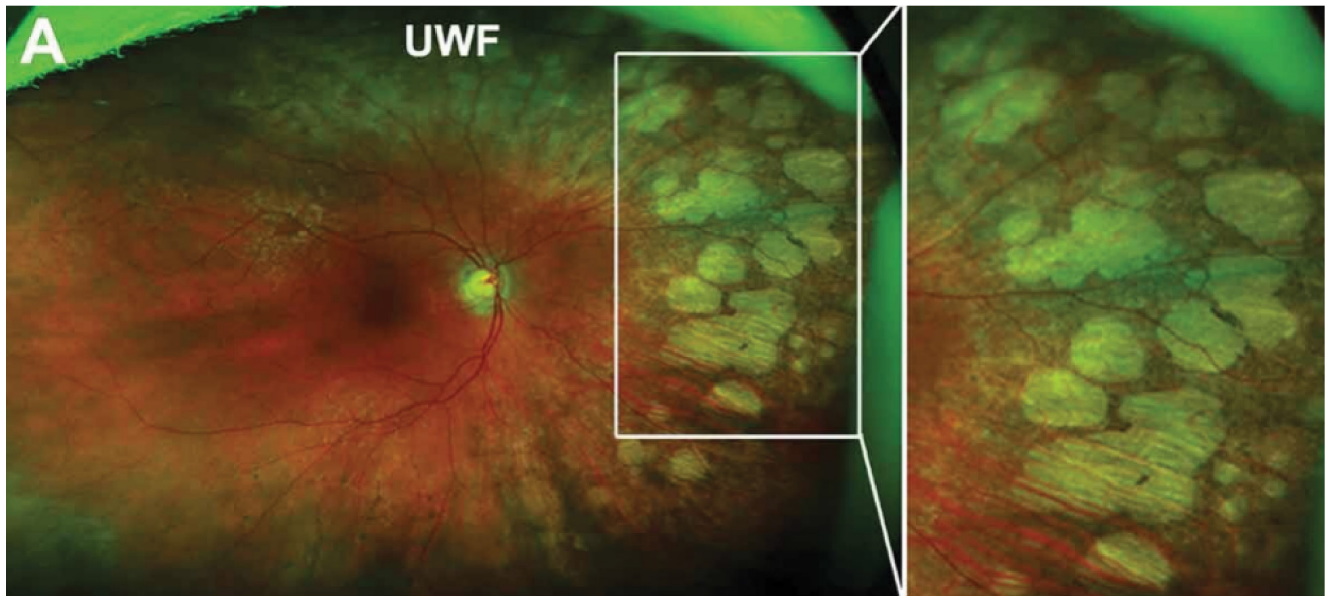
## **C) Chorioretinal Degeneration**

### **Pavingstone Degeneration**

Multiple rounded areas of choroidal and retinal atrophy, characterized by yellow-white lesions with discrete margins, may reveal underlying choroidal vessels as the sclera



**Figure 12.** Ultra-wide field photo of the right eye showing atrophic hole within an area of lattice degeneration; courtesy of Cheung R, Ly A, Katalinic P, Minas Theodore Coroneo, Chang A, Kalloniatis M, et al. *Visualisation of peripheral retinal degenerations and anomalies with ocular imaging. Seminars in Ophthalmology. 2022 Mar 7;37(5):554–82.*



**Figure 13.** Ultra-wide field of the right eye showing pavingstone degeneration nasal to the optic nerve; courtesy of Cheung R, Ly A, Katalinic P, Minas Theodore Coroneo, Chang A, Kalloniatis M, et al. *Visualisation of peripheral retinal degenerations and anomalies with ocular imaging. Seminars in Ophthalmology. 2022 Mar 7;37(5):554–82.*

becomes partly visible through the atrophic choroid. These lesions, which may merge, are typically found between the ora and equator, ranging from one to several disc diameters in size, with a predilection for the infero-nasal and temporal quadrants. Large choroidal vessels are often visible within the lesions. Prevalent in 4–28% of patients, occurring bilaterally with no gender predilection, these lesions increase in frequency with age but are benign and not associated with complications (**Figure 13**).<sup>18</sup>

### Peripheral Retinal Drusen

Extracellular protein and fat deposits commonly form between the retinal pigment epithelium (RPE) and Bruch's membrane, stemming from the degeneration of RPE cells. These deposits, characterized by a crystalline appearance, are typically small, round and distinctly outlined. They are frequently encountered in individuals age 40 years or older and are associated with benign degenerative changes. Prophylactic laser treatment is generally not considered necessary for managing these deposits.

### Conclusion

The decision to perform prophylactic laser treatment in peripheral retinal diseases is guided by several factors, including the underlying pathology, risk of progression to sight-threatening complications, patient-specific characteristics, and available clinical evidence.

The AAO preferred practice patterns (**Table 1**) serve as a good guideline when determining whether to treat or observe peripheral retinal conditions.

As the adoption of wide field imaging modalities such as SS-OCT grows the ultra-structural imaging will expand our understanding of peripheral retinal pathologies and how they interact with the overlying vitreous and underlying RPE to more objectively and effectively guide our management in the future.

### Correspondence:

**Ravi Dookeran, MD**

Email: r.dookeran@icloud.com

### Financial disclosures

**R.D.:** Consulting Panels and Speaker Honoraria:

Bayer, Roche, Apellis (none applicable to the contents of this article).

**C.W.:** None declared.

### References

1. Campagnoli TR, Smiddy WE. Peripheral retinal abnormalities. Springer eBooks. 2016 Jan 1;243–7.
2. Management options for peripheral retinal lesions. Adapted from American Academy of Ophthalmology. AAO PPP Retina/Vitreous Committee, Hoskins Center for Quality Eye Care. Preferred Practice Pattern: Posterior Vitreous Detachment, Retinal Breaks, and Lattice Degeneration PPP last revision by AAO 2022.
3. Quinn N, Csincsik L, Flynn E, et al. The clinical relevance of visualizing the peripheral retina. *Progress in Retinal and Eye Research* [Internet]. 2019 Jan 1 [cited 2022 May 11];68:83-109.
4. Peripheral Retinal Degenerations - EyeWiki [Internet]. eyewiki.aao.org.
5. Mandura RA. Acquired senile retinoschisis of the peripheral retina imaged by Spectral Domain Optical Coherent Tomography. *Cureus*. 2021 Apr 18;13(4):e14540.
6. Steven Ness, MD\* et al. Diagnosis and management of degenerative retinoschisis and related complications. *Survey of Ophthalmology*. 67: 2022: 892–907
7. Buch H, Vinding T, Nielsen NV. Prevalence and long-term natural course of retinoschisis among elderly individuals. *Ophthalmology*. 2007 Apr;114(4):751-5.
8. Cheung R, Ly A, Katalinic P, et al. Visualisation of peripheral retinal degenerations and anomalies with ocular imaging. *Seminars in Ophthalmology*. 2022 Mar 7;37(5):554-82.
9. Shukla M, Ahuja OP. White with pressure (WWP) and white without pressure (WWOP) lesions. *Indian J Ophthalmol*. 1982 May;30(3):129–32. PMID: 7174054.
10. Yu H, Luo H, Zhang X, et al. Analysis of white and dark without pressure in a young myopic group based on ultra-wide swept-source optical coherence tomography angiography. *J Clin Med*. 2022 Aug 18;11(16):4830.
11. Nishitsuka K, Nishi K, Namba H, et al. Peripheral cystoid degeneration finding using intraoperative optical coherence tomography in rhegmatogenous retinal detachment. *Clin Ophthalmol*. 2021 Mar 18;15:1183-7.



12. Shaimova VA. Peripheral retinal degenerations : optical coherence tomography and retinal laser coagulation. Cham, Switzerland: Springer; 2017.
13. Byer NE. Long-term natural history of lattice degeneration of the retina. *Ophthalmology*. 1989;96(9):1396-1402.
14. Michael J. Morano, MD, et al. Incidence and Risk Factors for Retinal Detachment and Retinal Tear after Cataract Surgery IRIS Registry (Intelligent Research in Sight) Analysis on behalf of the IRIS Registry Analytic Center Consortium. *Ophthalmology Science* December 2023 Volume 3, Number 4
15. Rutnin U, Schepens CL. Fundus appearance in normal eyes. Peripheral degenerations. *American Journal of Ophthalmology*. Dec. 1967;64:1040-62.
16. Maltsev et al. Spotlight on Lattice Degeneration Imaging Techniques. *Clinical Ophthalmology* 2023;17 2383-2395
17. Francone, Anibal et al. Detection of Neurosensory Retinal Detachment Complicating Degenerative Retinoschisis by Ultra Wide Field Fundus Autofluorescence Imaging. *RETINA, The Journal of Retinal and Vitreous Diseases* 2020 Volume 40 Number 5 819-824.
18. O'Malley P, Allen RA, Straatsma BR, et al. Paving-stone degeneration of the retina. *Arch Ophthalmol*. 1965;73:169-82